

# The treatment of herpes labialis with a diode laser (970 nm)—a field study

Dr Simone Suppelt

## ABSTRACT

Herpes labialis is an infection caused by the herpes simplex virus HSV 1 and, less frequently, HSV 2. In dental practices the diode laser is mainly used in periodontology, endodontics and minimally invasive surgery. Many of those affected by herpes are unaware that laser treatment can successfully alleviate their symptoms.

In this field study, 11 patients who suffer from acute herpes were treated with a 970 nm diode laser. The areas which the patients described as being affected by herpes were irradiated at a distance of 1–3 mm (2.0 W, 10 Hz, 50 % duty cycle, 320 µm optical fiber).

Several patients felt the symptoms subside during the treatment. For the majority of patients, the symptoms did not occur again after treatment. All of the patients were satisfied with the treatment.

Laser treatment of herpes labialis using a 970 nm diode laser is an effective way for me to help my patients both quickly and simply.

## KEYWORDS

Diode laser, 970 nm, herpes labialis, HSV

## Introduction

With a wavelength of 970 nm and a maximum output of 7 W cw, the SIROLaser Advance dental diode laser has a wide range of indications. In my practice, the laser is mainly used in periodontology and endodontics to reduce germs in pockets or in root canals. I also use the laser for small surgical procedures, such as removing fibromas, separating the labial frenulum, operculectomies or opening abscesses. The advantages of laser treatment in surgery are clean incisions, the hemostatic effect, the reduction in germs along the incision and the related quick healing of wounds without scarring. For the indications that I treat, the laser offers preset and adequate treatment parameters such as output, pulse frequency and duty cycle. The treatment process is made significantly easier as these parameters can be accessed in the menu. In addition to these frequent indications, I use the laser to treat herpes labialis.

Herpes simplex viruses (HSV) cause various infection types. Around the world, around 60–95% of adults are affected by HSV.<sup>1</sup> Herpes labialis (also referred to as a cold sore) is probably the most common form which is essentially triggered by the herpes simplex virus type 1. The initial infection (often in the form of herpetic gingivostomatitis) may even be asymptomatic, following this the HSV persist in the body and repeat episodes can vary in terms of their nature, severity and frequency. The initial infection can lead to severe complications, particularly in infants and small children.

An outbreak of herpes labialis can be accompanied by various symptoms. As a rule, in the early stages such symptoms include dry lips and a tingling/itching sensation. In subsequent stages, swelling and a feeling of tightness occur which can rapidly be accompanied by a sensation of burning or other sense of pain. Blisters can subsequently form which may then burst open and scab over.

Herpes infections are often not treated as they normally heal by themselves after 10–14 days. Superficial anti-viral treatment using ointments is well known (e.g., aciclovir and penciclovir).<sup>2</sup>

The treatment of herpes labialis with the aid of a diode laser offers the dentist the interesting option of extending the range of applications in his practice and also alleviating the pain suffered by patients both quickly and simply.

Studies with different approaches confirm the success of laser treatment:

- a) Photodynamic therapy can be used as an effective treatment option.<sup>3</sup> This reduces the frequency of the occurrence of herpes labialis and also reduces the time required for the infection to heal.
- b) Repeat laser treatment with 690 nm (diode) and a lower intensity can be used to reduce the frequency of reoccurrence of herpes infections.<sup>4</sup> Jovanovic et al. recommend the use of a helium neon laser (633 nm) given its properties which reduce pain and shorten the herpes infection.<sup>5</sup>

c) In the higher intensity range, initial treatment trials with the Nd:YAG back in 1999 resulted in a reduction in symptoms and stopped the further course of the herpes infection.<sup>6</sup> Moghtader reported on the successful treatment of herpes labialis with a combination of higher intensity (1.5 W pulsed, 1,500 Hz, average output 1 W) and soft laser (100 mW, one minute).<sup>7</sup>

### Materials and methods

Eleven patients (Fig. 1) were included in the field study once differential diagnoses such as recurrent aphthous ulcers, herpes zoster, herpes with HIV, erythema multiforme and contact dermatitis were all ruled out. The patients were asked to give their name and gender and to describe the normal course after the outbreak of herpes, the frequency of outbreaks and current symptoms. Following this, the patients were treated with a SIROLaser Advance (Sirona Dental Systems GmbH, Bensheim, Germany).

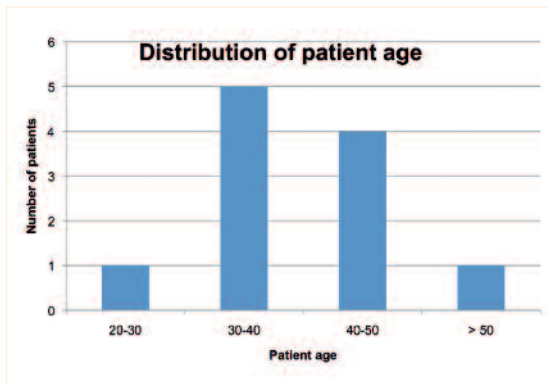


Fig. 1: Age distribution of the patient population in the herpes field study

The eleven patients in this field study suffer to differing degrees from herpes labialis with outbreaks ranging between 1 and 12 times a year (Fig. 2).

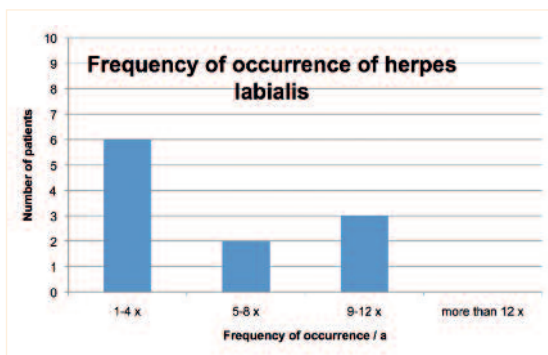


Fig. 2: Frequency of occurrence of herpes labialis in the patient population.

The symptoms of outbreaking herpes infections vary from patient to patient. Blister formation is the only almost universal symptom (Tab. 1).

When you suffer from herpes—which symptoms do you experience? (multiple answers possible)	Number of patients
Dry lips	6
Tingling, itching sensation	7
Burning, sensation of pain	6
Swelling, feeling of tightness	7
Blister formation	10
Bursting of blisters and scab formation	7
Secondary inflammation	-
Other	-

Tab. 1: The various patients displayed different symptoms during an outbreak of herpes.

The stage of the herpes infection at the time of participation in the field study had varying manifestations (Tab. 2).

At what stage are you now during laser treatment? (multiple answers possible)	Number of patients
Dry lips	2
Tingling, itching sensation	3
Burning, sensation of pain	4
Swelling, feeling of tightness	8
Blister formation	6
Bursting of blisters and scab formation	-
Secondary inflammation	-

Tab. 2: Stage of herpes labialis prior to treatment.

Treatment was performed with the SIROLaser Advance, a 970 nm diode laser from Sirona Dental Systems GmbH. Using the manufacturer’s treatment settings—2.0W, 10 Hz, 50% duty cycle, 320 µm optical fiber—the lip areas described by the patients as being affected by herpes were each irradiated three times at a distance of 1–3 mm for 30 seconds. In addition the patients were asked to indicate any sensation of pain, at which point the distance was increased up to 8 mm. Patients who continued to experience symptoms were allowed to repeat the treatment.

### Results

All patients felt a sensation of warmth during treatment. In several cases the tingling, itching, burning and sense of pain as well as the feeling of tightness subsided even during the treatment (Tab. 3).

What did you feel during the treatment?	Number of patients
Sensation of warmth	11
Reduction in tingling and itching	3
Reduction in burning and sense of pain	3
Easing of swelling	3

Tab. 3: Symptoms during treatment.

Which stages have not reoccurred since treatment?	Number of patients
Burning, sensation of pain	6
Swelling, feeling of tightness	4
Blister formation	6
Bursting of blisters and scab formation	4
Secondary inflammation	2

**Tab. 4:** Symptoms which no longer occurred after treatment.

Seven of the eleven patients were so satisfied with the result after the first treatment that they did not require a second treatment. One patient was treated twice, another three times and another six times.

After treatment, some patients confirmed that certain symptoms no longer occurred (Tab. 4). This indicates that the duration of the herpes infection is reduced by means of laser treatment.

All the patients (100%) were satisfied with the laser treatment of their herpes labialis which was undoubtedly due in part to the fact that, on the one hand, the effects were seen quickly and, on the other hand, none of the patients suffered any complications or complaints as a result of the laser treatment.

## Discussion

Compared to treatments in studies with lower intensity, treatment with the SIROLaser Advance has a considerably higher applied irradiance. Whilst with Jovanovic et al. 14–32 mW/cm<sup>2</sup> was used for irradiation, a value which is typical for soft laser treatment and LLLT, the figure in this study was, in absolute terms, 48–222 W/cm<sup>2</sup>, i.e., more than a thousand times greater. The corresponding values from Moghtader are, at approx. 8–12 W/cm<sup>2</sup>, mathematically slightly below those of the SIROLaser (a diameter of 4 mm is given for the irradiation area). In principle, Jovanovic treated her patients five times for an irradiation time of 5 minutes. She reported a decrease in symptoms after the first treatment. According to Moghtader “as a rule” a patient is pain-free after 24 hours, otherwise a second sitting follows. With the SIROLaser, too, one sitting was sufficient in 64% of all cases. A correlation between the speed of the reduction of symptoms and irradiance should be investigated; however a systematic assessment is beyond the realms of what is possible in a registered practice.

The spontaneous reduction of symptoms during and after laser treatment results in a considerable easing of the complaints caused by herpes labialis. Treatment would appear to be more successful the sooner the patient begins with the laser treatment after the start of the herpes infection. This field study confirmed to me that laser treatment of herpes labialis is a very good way to quickly and simply help my patients without any side effects. ◀

## Literature

1. Chayavichitsilp P, Buckwalter JV, Krakowski AC, Friedlander SF. Herpes Simplex, *Pediatr Rev.* 2009;30 (4):119–129.
2. Raborn GW, Grace MG. Recurrent herpes simplex labialis: selected therapeutic options, *J Can Dent Assoc.* 2003 Sep;69 (8):498–503.
3. Marotti J, Aranha AC, Eduardo Cde P, Ribeiro MS. Photodynamic therapy can be effective as a treatment for herpes simplex labialis, *Photomed Laser Surg.* 2009 Apr;27 (2):357–363.
4. Schindl A, Neumann R. Low-intensity laser therapy is an effective treatment for recurrent herpes simplex infection. Results from a randomized double-blind placebo-controlled study, *J Invest Dermatol.* 1999 Aug;113 (2):221–223.
5. Jovanovic L, Mirkovic B, & Zivkovic B. Soft Laser in the Therapy of Herpes Simplex Labialis, *The scientific journal Facta Universitatis, Series: Medicine and Biology* 1998;5 (1):61–63.
6. Parkins FM, O'Toole TJ, Yancey JM, Nd:YAG laser treatment of herpes and aphthous ulcers: a preliminary study, *Proc. SPIE 1466, Laser Florence '99: A Window on the Laser Medicine World*, 253 (June 28, 2000).
7. Moghtader D. Herpes Labialis einfach, schnell und nachhaltig therapieren, *Laser Journal* 2001;4:18–19.