

## Excision of Capillary Hemangioma by Diode Laser

**Akash Bhatnagar\* and Mahendra Kumar Jindal**

*Department of Paediatric and Preventive Dentistry, Dr. Z.A Dental College and Hospital, AMU, Aligarh, Uttar Pradesh, India*

**\*Corresponding Author:** Akash Bhatnagar, Assistant Professor, Department of Paediatric and Preventive Dentistry, Dr. Z.A Dental College and Hospital, AMU, Aligarh, Uttar Pradesh, India.

**Received:** June 27, 2017; **Published:** August 01, 2017

### Abstract

An acquired or congenital vascular lesion arises from malformation in blood vessels or endothelial cell proliferation. Capillary hemangiomas are composed by small blood capillaries surrounded by a covering of endothelial cells in a connective tissue. Various treatments options are available nowadays, like complete excisional surgery, sclerotherapy and laser excision. In this present case report, we reported a successful diode laser excision of intraoral capillary hemangioma present on inner surface of lower lip.

**Keywords:** *Vascular Malformation; Hemangioma; Diode Laser; Excisional Surgery; Laser Excision*

### Introduction

Hemangioma is a benign malformation of blood vessels, mostly seen during infancy. It is affecting 10 - 12% of children under 1 year of age. In infants, hemangioma commonly occurs in head and neck region and seen more frequently in palate, lips and tongue [1]. The main etiology of hemangioma is still unknown but it is related to some other conditions like low infant birth weight, gestational hypertension and child bearing age [2].

Hemangioma can be divided into three types: a) Capillary Hemangioma b) Cavernous Hemangioma c) Mixed type [1].

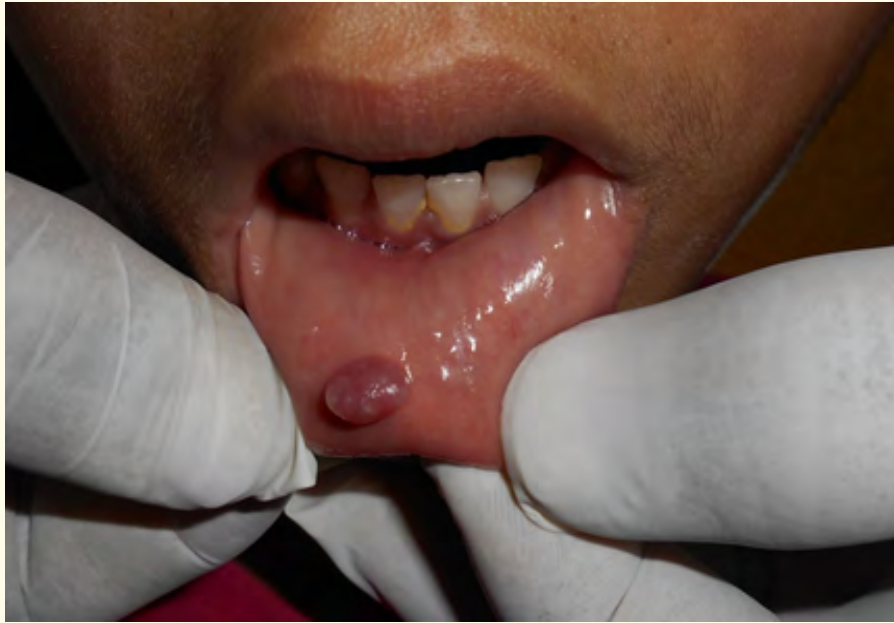Capillary hemangiomas are composed by small blood capillaries surrounded by a covering of endothelial cells in a connective tissue. Capillary hemangioma is commonly seen in head and neck region but mostly occur in lip, palate, oral mucosa and tongue [3].

Different treatment options are available like incisional or excisional surgery, sclerotherapy, embolization, X-ray therapy and laser treatment. Diode and Nd:YAG lasers are commonly used for soft tissue excision due to haemostatic property provided by more deep penetration and high absorption in hemoglobin [4].

In this case report, we present a case of diode laser excision of capillary hemangioma involving lower lip in an 11 years old girl.

### Case Report

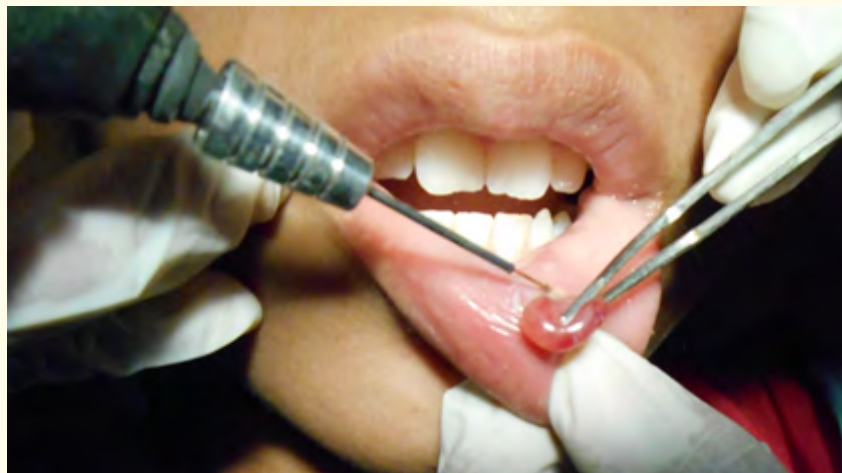An 11 years old healthy female child reported with the chief complaint of swelling on inner surface of lower lip since 2 months. Patient was asymptomatic 2 months back when she noticed a small elevation present on the inner surface of the lower lip. Patient noticed that the size of the projection gradually increased and attained the present size. It was not associated with any pain/ burning sensation/pus discharge. The lesion was solitary, fluctuant and well - circumscribed present on the lower labial mucosa; slightly right to the midline. It was faintly bluish in color, around 8 - 9 mm in diameter, flaccid in consistency, soft on palpation, nontender & had a smooth overlying and surrounding surface (Figure 1).



**Figure 1:** Pre-Operative view of lesion.

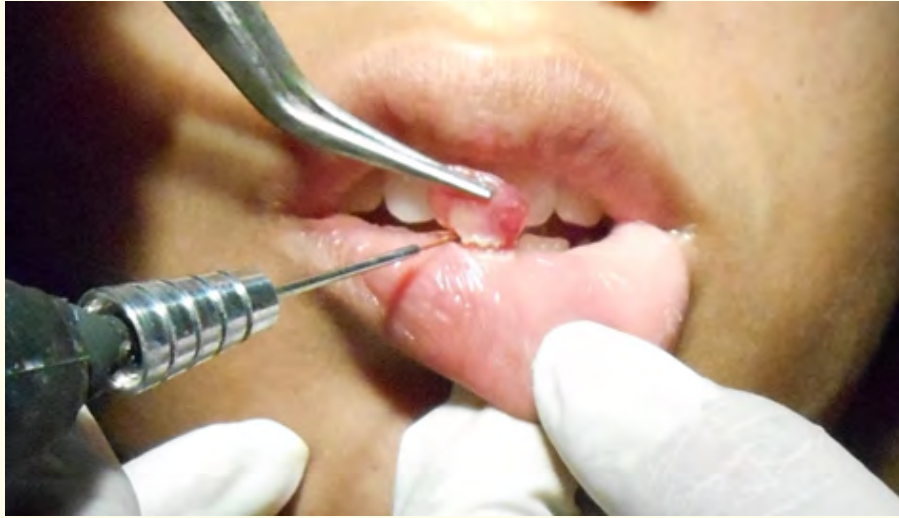The patient's parents were informed about both surgical and laser treatment options for the capillary hemangioma, and they opted for laser excision. 2% lignocaine topical anesthetic was sprayed on and around the lesion on lower lip. A 970-nm diode laser (Fona Laser) with a fiber tip of diameter 320  $\mu\text{m}$  was used in this case for excision. Special filter goggles were worn by the child, Pediatric dentist, and the assistant before starting the procedure.

The periphery of the lesion on lower lip was first marked with diode laser fiber tip in contact mode at low power setting (1.3 Watts, 0.10 ms pulse interval, 0.05 ms pulse duration) to determine the extent of the excision of capillary hemangioma (Figure 2).



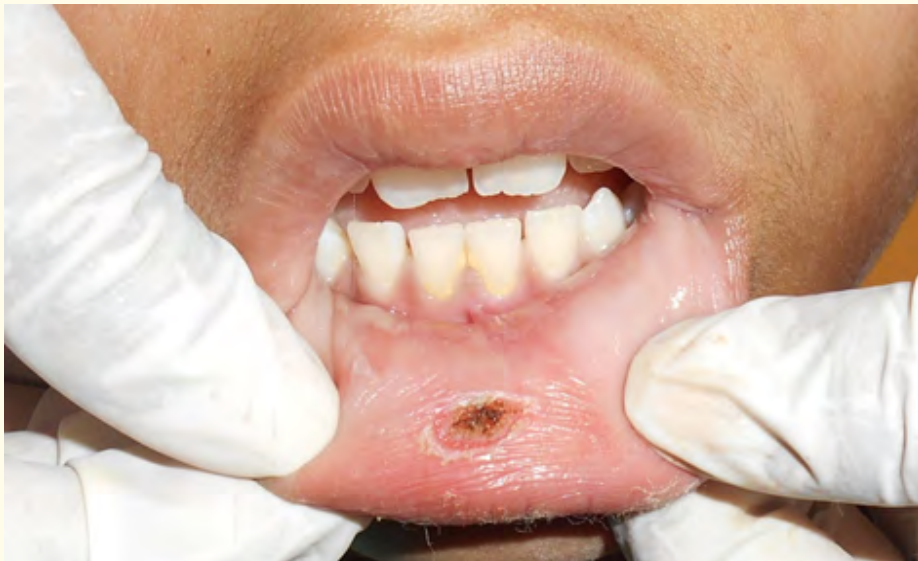**Figure 2:** Demarcation of Periphery of the lesion.

320  $\mu\text{m}$  fiber tip was used in contact mode at high power setting (1.7 Watts, 0.10 ms pulse interval, 0.05 ms pulse duration) in to-and-fro motion to complete the excision of the lesion (Figure 3).

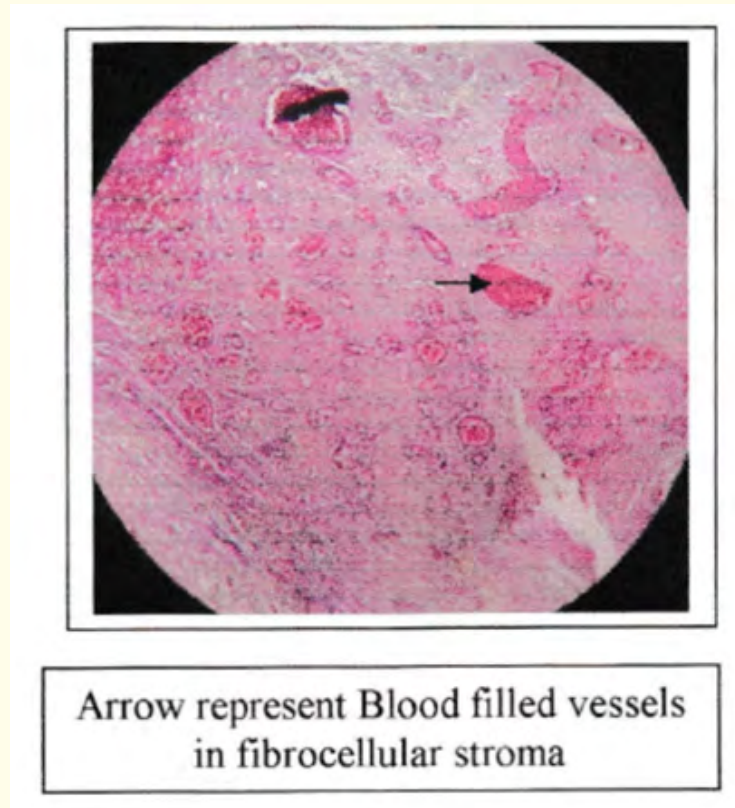


**Figure 3:** Excision of the lesion.

After complete laser excision, lesion was sent for histopathological examination. On the basis of clinical and histopathological examinations, it was confirmed the diagnosis of capillary hemangioma of lower lip (Figure 4,5).

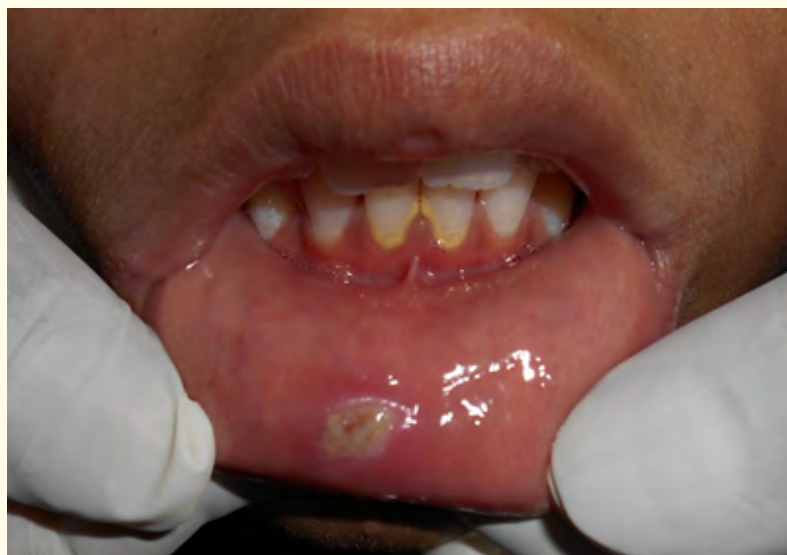

**Figure 4:** After excision of the lesion.

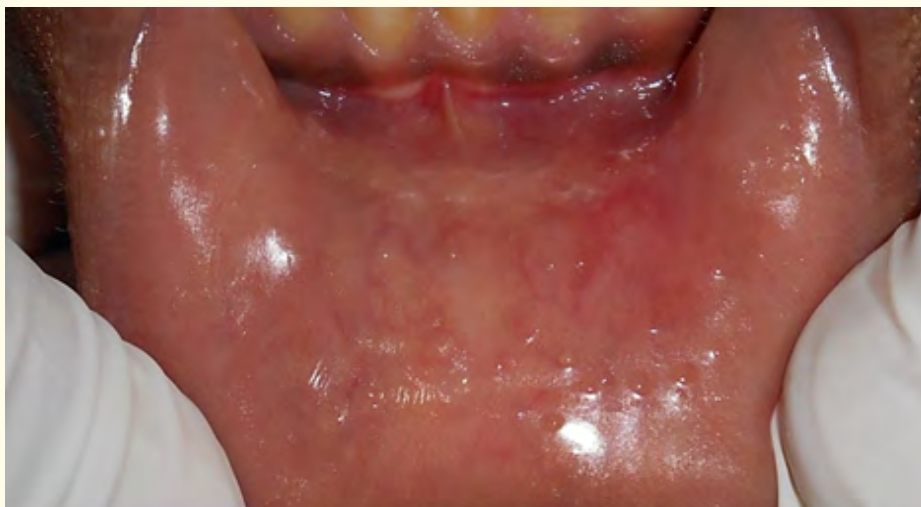

*Figure 5: Histopathological Features.*

Patient was recalled on follow-up at 7 days, 21 days and 1 month and also advised not to take spicy and hot food for a day. There had been no recurrence of the lesion over the 6 months (Figure 6,7).



*Figure 6: Post-Operative view after 7 days.*



*Figure 7: Post-Operative view after 1 Month.*

## Discussion

In children one of the most common benign tumors of vascular origin is Hemangioma. Capillary hemangiomas are composed of small blood capillaries and looks like soft reddish mass, sessile or pedunculated in different sizes. In some cases, bleeding and surface ulceration can be observed [1,5].

There are different treatment options available nowadays, but it is very important to select a suitable treatment option according to size, shape, location and clinical condition of the lesion. Conventional surgical excision of the lesion may be followed by some complication like excessive bleeding. To overcome these complications, laser excision can be used for this lesion [6]. In the present case, no intraoperative and postoperative pain was reported by patient [2].

Diode laser is an excellent soft tissue laser. It has good affinity for hemoglobin pigments and therefore has good haemostatic capability. These lasers are poorly absorbed by the tooth structure and so soft tissue laser surgery can be safely performed in close proximity to dental hard tissue [7]. Zheng JW, *et al.* (2008) reported that laser therapy is the main treatment option for oral capillary hemangioma [3].

In this case report, no bleeding was observed during laser excision which provided better vision for dentist. Other advantages of laser surgery were excellent healing, no postoperative swelling or pain, providing coagulation, and no need for suturing [8].

Thus, in case of Capillary Hemangioma of lower lip, diode laser excision is an effective form of treatment.

## Conclusion

The application of diode laser in treatment of oral hemangioma can be beneficial for both patients and clinicians due to less postoperative complications and providing simple surgical procedure with minimal side effects.

## Conflict of Interest

None.

### Source of Support

Nil.

### Bibliography

1. Coletton S. "Lasers in surgical periodontics and oral medicine". *Dental Clinics of North America* 48.4 (2004): 937-962.
2. Lambrecht JT, et al. "Co<sub>2</sub> laser therapy for intraoral hemangiomas". *Journal of Oral Laser Application* 4.2 (2004): 89-96.
3. Zheng JW, et al. "Management of head and neck hemangiomas in China". *Chinese Medical Journal* 121.11 (2008): 1037-1042.
4. Gontijo I, et al. "The applications of diode and Er; YAG lasers in labial frenectomy in infant patients". *Journal of Dentistry for Children* 72.1 (2005): 10-16.
5. Fekrazad R, et al. "Defocused Irradiation Mode of Diode Laser for Conservative Treatment of Oral Hemangioma". *Journal of Lasers in Medical Sciences* 4.3 (2013): 147-150.
6. Karasu HA, et al. "Cryosurgery of a Huge Hemangioma of Tongue: A Case Report". *Journal of Oral Health and Community Dentistry* 4.3 (2010): 83-87.
7. Hiremath SS, et al. "Oral Hobnail Hemangioma: A Case Report". *Archives of Iranian Medicine* 16.7 (2013): 428-430.
8. Mott A. "Using an 810-nm diode laser to remove a venous lake". *Journal of Laser Dentistry* 18.1 (2010): 17-18.

**Volume 13 Issue 1 August 2017**

**© All rights reserved by Akash Bhatnagar and Mahendra Kumar Jindal.**